


# BODY FLUIDS ANALYSIS **iQ200**

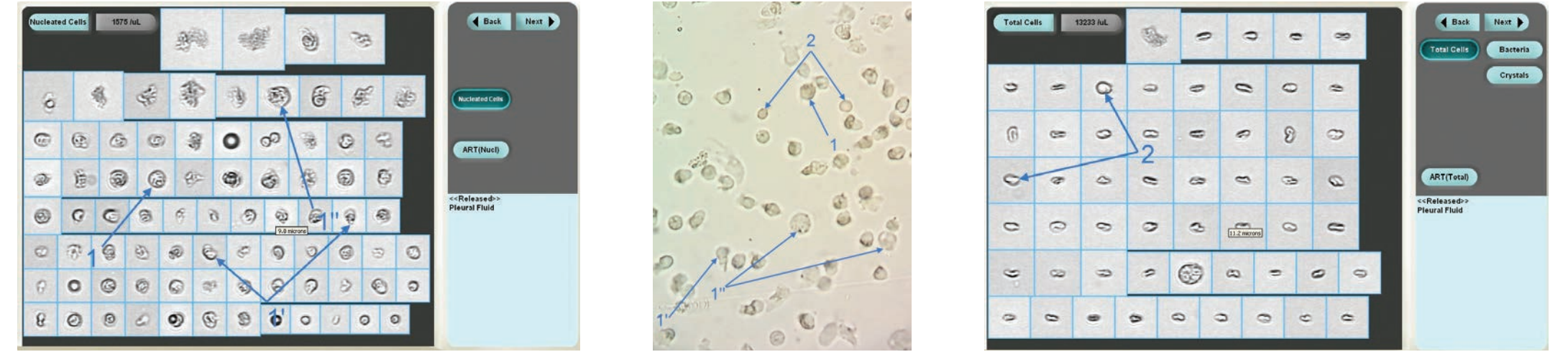## COMPARISON AND EVALUATION: BODY FLUIDS ANALYSIS ON THE iQ200 AUTOMATED BODY FLUIDS MODULE VS. MANUAL MICROSCOPY

DR. SORIN GIJU, PH.D., OF CLINICAL EMERGENCY HOSPITAL TIMISOARA, ROMANIA


iQ200 digital flow morphology automates body fluids analysis using digital microscopy imaging with direct correlation to the manual method. An extensive image comparison study—conducted by Sorin Giju, Ph.D., clinical chemist and lead of the Urinary Biochemistry department at Clinical Emergency Hospital Timisoara, Romania—analyzed body fluid particle images captured by the iQ200 and manual microscopy using filters on the same patient sample. As displayed below, Dr. Giju's study shows strong correlation between the two methods.



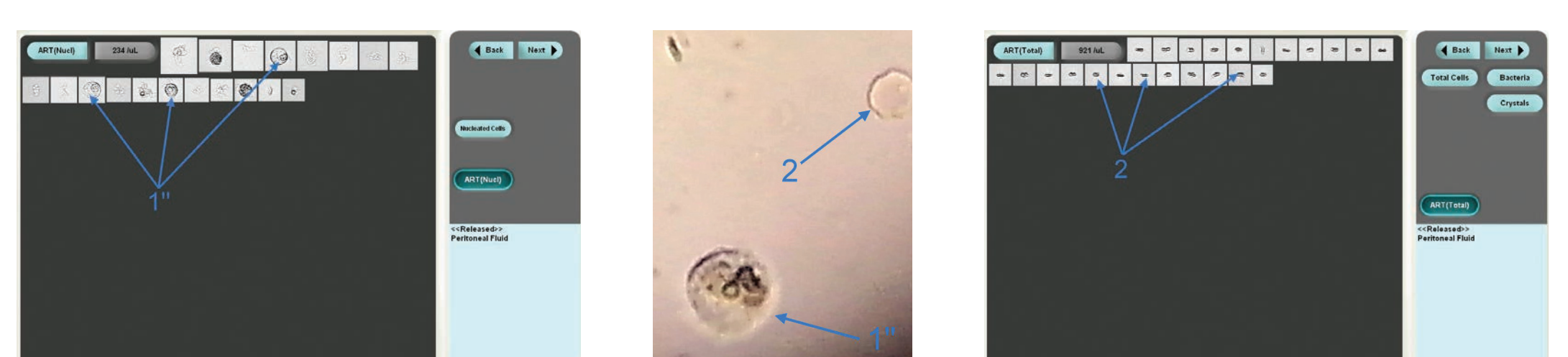**FIGURE 1** | Created red blood cells (2) and leukocytes (1) from meningeal bleeding, a probable indication of meningeal inflammation. Native unstained preparation. B.F.M x 640 (personal collection)



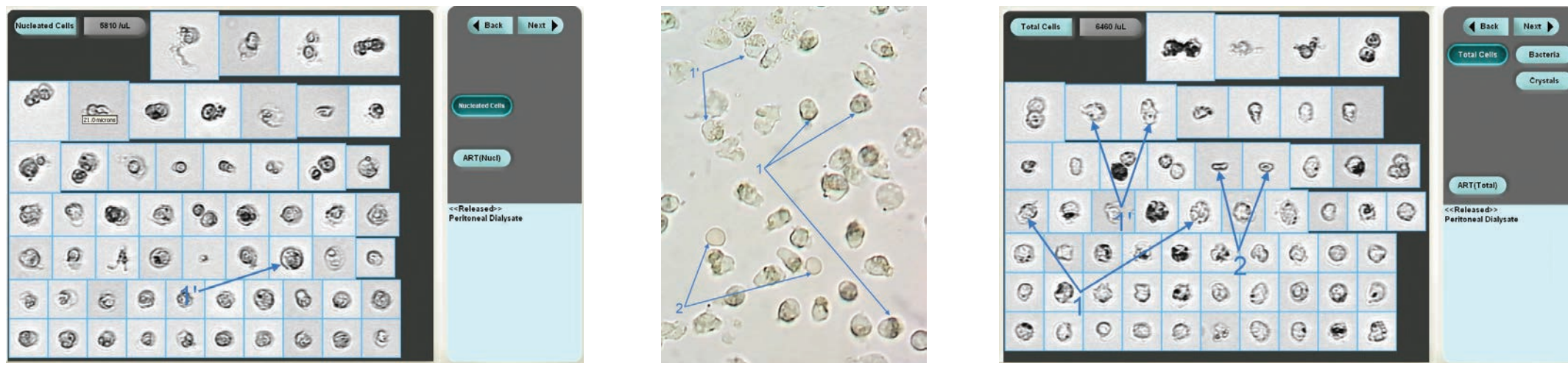
**FIGURE 8** | Normal leukocytes (1), normal isomorphic red blood cells (2), enlarged normal leukocytes due to a hypotonic environment (the Brownian motion creating the appearance of glittering cells (1)), and elongated and broken leukocytes (1). Sample obtained from pleural fluid puncture performed on a patient experiencing pleurisy. Native unstained preparation. B.F.M x 640 (personal collection)



**FIGURE 2** | Isomorphic erythrocytes disc cells (2) and leukocytes (1), which are most frequently the result of an accidental puncture, in this case a probable indication of meningeal inflammation, or possibly meningitis. Native unstained preparation. B.F.M x 640 (personal collection)



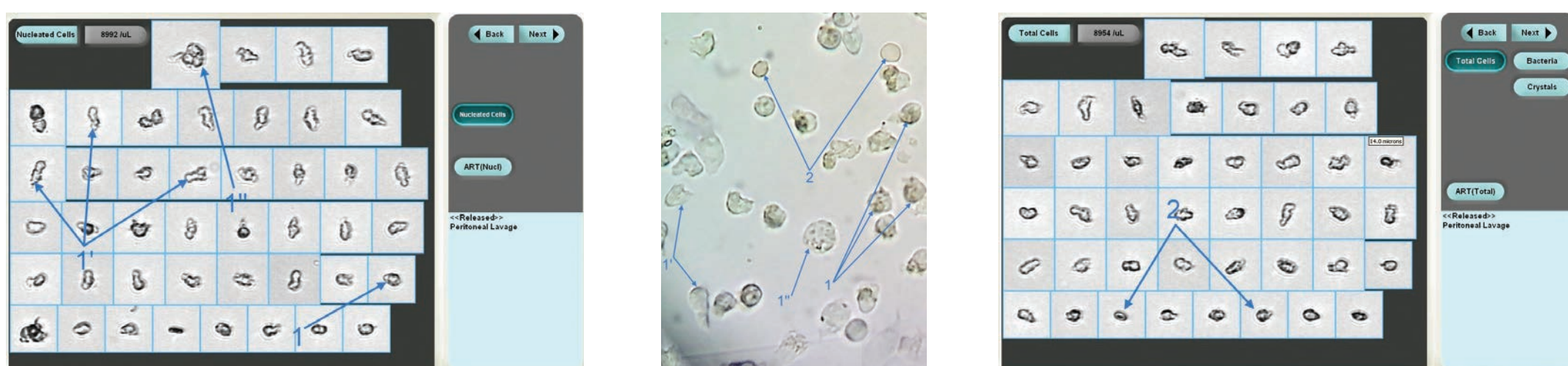
**FIGURE 9** | Normal leukocytes (1), normal isomorphic red blood cells (2), enlarged normal leukocytes due to a hypotonic environment (the Brownian motion creating the appearance of glittering cells (1)), normal isomorphic red blood cells (2). Peritoneal fluid obtained from patient with peritonitis. Native unstained preparation. B.F.M x 640 (personal collection)



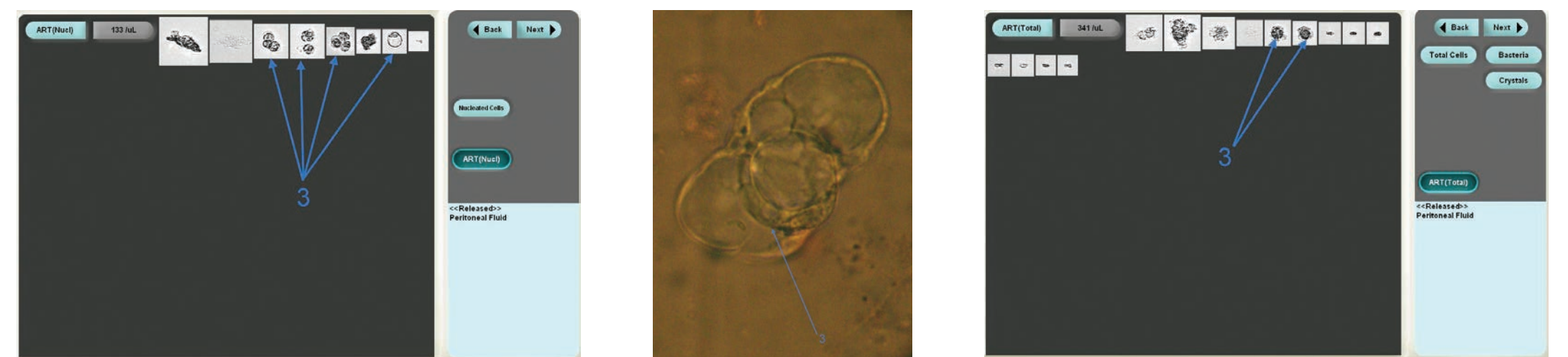**FIGURE 3** | Enlarged leukocytes due to a hypotonic environment (the Brownian motion creating the appearance of glittering cells (1)), normal leukocytes (1), and normal isomorphic red blood cells (2): an indication of peritonitis. Native unstained preparation. B.F.M x 640 (personal collection)



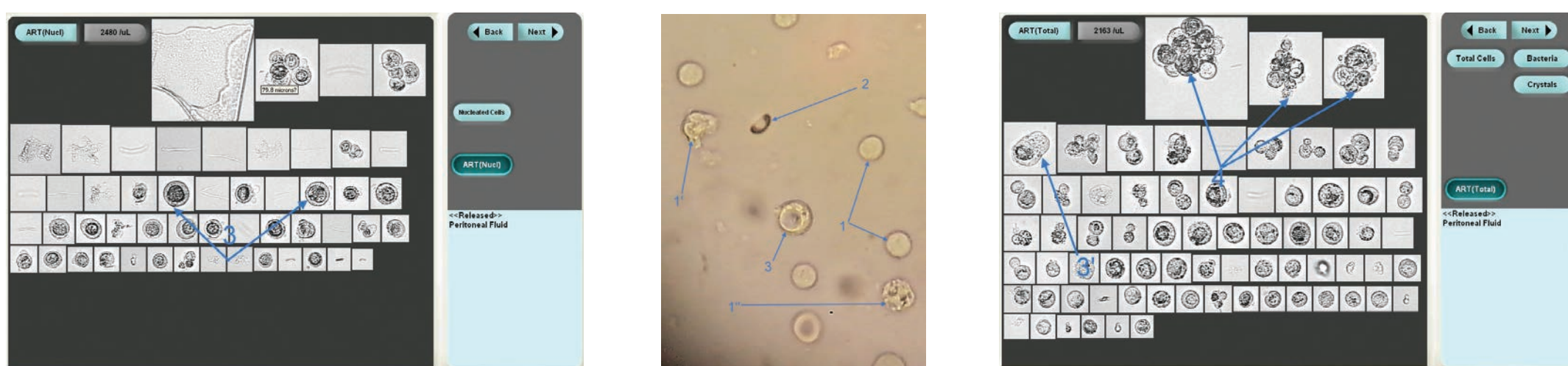
**FIGURE 10** | Leukocytes (1), broken leukocytes (1), normal isomorphic red blood cells (2), and atypical cells (3) from peritoneal fluid, a display of the phenomenon known as cellular cannibalism, which is specific to malignant tumors. Peritoneal fluid obtained from patient with abdominal tumor and hepatic cirrhosis. Native unstained preparation. B.F.M x 640 (personal collection)




**FIGURE 4** | Normal leukocytes (1), normal isomorphic red blood cells (2), enlarged leukocytes due to a hypotonic environment (the Brownian motion creating the appearance of glittering cells (1)), and broken leukocytes (1). Sample from peritoneal lavage in a peritonitis case. Native unstained preparation. B.F.M x 640 (personal collection)



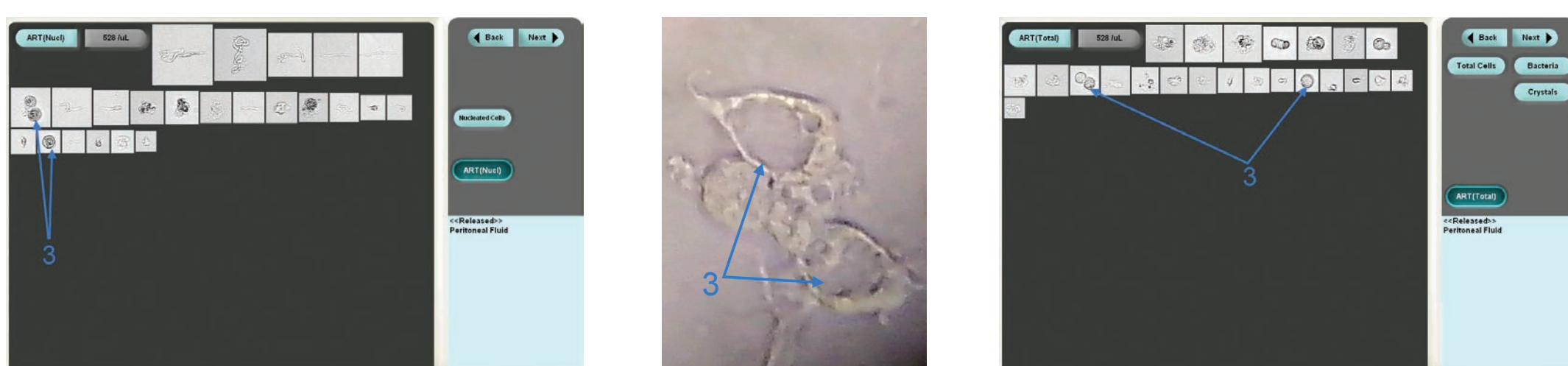**FIGURE 11** | Normal leukocytes (1) and normal isomorphic red blood cells (2) in hypotonic environment. Normal leukocytes will become enlarged due to the environment (the Brownian motion creating the appearance of glittering cells (1)). Sample obtained from pleural fluid puncture. Native unstained preparation. B.F.M x 640 (personal collection)



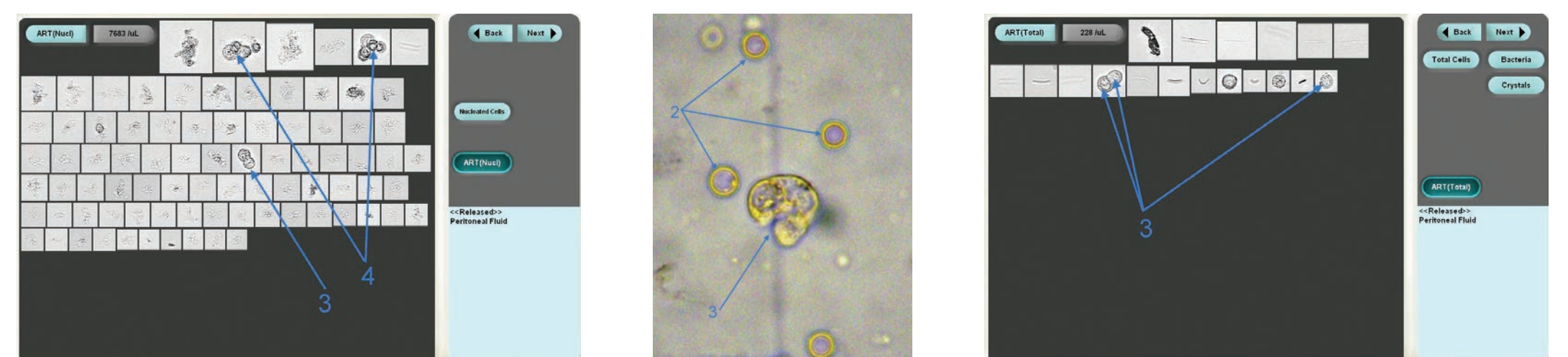
**FIGURE 5** | Normal leukocytes (1), enlarged leukocytes (1), broken leukocytes (1), normal isomorphic red blood cells (2), atypical cells (3), and several atypical cells clumps (4) from a peritoneal fluid, a display of the phenomenon known as cellular cannibalism, which is specific to malignant tumors. Peritoneal fluid obtained from patient with a hepatic tumor experiencing complications from peritonitis. Native unstained preparation. B.F.M x 640 (personal collection)




**FIGURE 12** | Leukocytes (1), normal isomorphic red blood cells (2), atypical cells (3), and several atypical cells clumps (4) from peritoneal fluid, a display of the phenomenon known as cellular cannibalism, which is specific to malignant tumors. Peritoneal fluid obtained from patient with hepatic tumor experiencing complications from peritonitis. Native unstained preparation. B.F.M x 640 (personal collection)



**FIGURE 6** | Leukocytes (1), enlarged leukocytes due to a hypotonic environment (the Brownian motion creating the appearance of glittering cells (1)), broken leukocytes (1), normal isomorphic red blood cells (2), and atypical cells (3) from peritoneal fluid, a display of the phenomenon known as cellular cannibalism, which is specific to malignant tumors. Peritoneal fluid obtained from patient with abdominal tumor experiencing complications from peritonitis. Native unstained preparation. B.F.M x 640 (personal collection)



**FIGURE 13** | Leukocytes (1), normal isomorphic red blood cells (2), atypical cells (3), and several atypical cells clumps (4) from peritoneal fluid, a display of the phenomenon known as cellular cannibalism, which is specific to malignant tumors. Peritoneal fluid obtained from patient with abdominal and hepatic cirrhosis. Native unstained preparation. B.F.M x 640 (personal collection)



**FIGURE 7** | Normal leukocytes (1), normal isomorphic red blood cells (2), enlarged normal leukocytes due to a hypotonic environment (the Brownian motion creating the appearance of glittering cells (1)), and elongated leukocytes (1). Sample obtained from peritoneal fluid puncture. Native unstained preparation. B.F.M x 640 (personal collection)